

# CLINICAL NEUROSCIENCE

66. ÉVFOLYAM



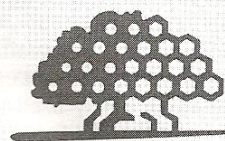
KÜLÖNLENYOMAT • 2013. MÁRCIUS 30.

## IDEGGYÓGYÁSZATI SZEMLE

Abstracts of the 6th Pannonian Symposium on  
CNS Injury

5-6th April, 2013, Pécs, Hungary

Ideggyogy Sz 2013;66(3-4):128-138.



**BANYAN**  
BIOMARKERS®



ESZA TÁRSADALMI SZÖLGAALTATÓ  
NONPROFIT KFT.

National Development Agency  
www.sztechenyiplan.gov.hu  
54 46 028 428

HUNGARY'S RENEWAL

The project is supported  
by the European Union.

**CODMAN NEURO**

 **DePuy Synthes**  
COMPANIES OF Johnson & Johnson



**PÉCSI TUDOMÁNYEGYETEM**  
UNIVERSITY OF PÉCS



**SZÉCHENYI PLAN**

L



M



36.4% had nausea and 27.3% had fatigue. Mean duration of retrograde amnesia was 15-30 minutes and mean duration of anterograde amnesia was less than 15 minutes. Most of patients were injured in traffic accidents (54.5%) and the others suffered falls and assaults 27.3% and 18.2% respectively. In three of twelve patients (25%) lesion on MRI examination were found. All of them had headache and both retrograde and anterograde amnesia longer than 30 minutes. Two of them were injured in assault and one in traffic accident. There were no other significant similarities between these patients.

*Conclusion:* These are only preliminary results of our study on small number of patients but they are matching results of similar investigations in literature. We plan to enroll more patients and try to find pattern to discover one with greater risk for structural brain damage so they can be diagnosed and treated properly. FLAIR, T2\* and SWI are commercially available sequences that can improve the diagnostic and prognostic ability of the neurosurgeon treating patients with mild traumatic brain injury.

#### **Prediction of long term outcome in patients suffered severe traumatic brain injuries using diffusion tensor imaging and probabilistic tractography**

Dávid Kis, Adrienn Máté, Andrea Czigner, Zoltán Mencser, Tamás Kincses, Pál Barzó  
SZTE, SZAKK, Idegsebészeti Klinika; SZTE, SZAKK, Neurológiai Klinika, Szeged

Traumatic brain injury (TBI) is among the leading causes of permanent disability. Techniques which reliably identify irreversibly injured brain areas would allow us to predict the long term outcome of severe TBI patients, thus indicate the need for aggressive treatment. Diffusion tensor imaging (DTI) and probabilistic tractography are powerful tools to quantitatively examine white matter integrity and create probabilistic connectivity (PC) maps at the individual level. Our aim was to identify structural abnormalities as biomarkers which can predict the long term outcome of the individual and are easy to use in the clinical practice. Magnetic resonance imaging (MRI) scans were performed in the subacute phase of the trauma using the following sequences: high resolution T1, fluid attenuation inversion recovery (FLAIR), susceptibility weighted imaging (SWI), T2 and DTI. From the DTI images fractional anisotropy (FA) and PC (connection to the medial and sensory thalamus, primary motor cortex) maps of the brain stem were reconstructed. In healthy controls (n=15) there was a high correlation between the FA and PC maps of the brain stem and the anatomical structure. Ten TBI patients were tested who had similar initial clinical and CT scores indicating same clinical outcomes. There was no significant correlation between the outcome and T1, T2, FLAIR and SWI abnormalities. In patients who remained in unconscious state (n=6) we observed disorganization of the FA and PC maps in the upper pons. In those who regained consciousness (n=8) the brain stem structure

showed no difference compared to the controls. In conclusion the FA and PC maps highly correlated with the clinical state at the individual level. According to our results DTI and probabilistic tractography may be clinically useful methods to predict long term outcome of severe TBI patients.

#### **A case of Traumatic Brain Injury (TBI) with persistent post-concussion symptoms: Response to Cranial Nerve Non-Invasive Neural Modulation (CN-NINM)**

George W. Kukurin

Private Practice Chiropractic Neurology, Palm Valley, Arizona, USA

*Background:* TBI is the leading cause of mortality and disability among young individuals in developed countries, and globally the incidence of TBI is rising sharply. Recent findings suggest that symptoms of TBI may persist long after the initial trauma. Effective treatment for the persistent sequelae of brain trauma is lacking and new effective treatments urgently needed. A case of a 28 year female mTBI patient who failed to respond to 18 months of therapy at a neurological specialty hospital is presented. Rapid objective clinical improvement following application of CN-NINM techniques is reported.

*Methods and Outcomes:* The technique of CN-NINM was pioneered by researchers at the University of Wisconsin Tactile Communication and Neurorehabilitation Laboratory (TCNL) (Wildenberg JC, Tyler ME, Danilov YP, Kaczmarek KA et al., 2011) The technique involves the application of a mild electrical current applied to the tongue through a stimulation device known as a PoNS™ unit for the purpose of activating structures of the central nervous system. Changes in cognitive function scores following CN-NINM are reported.

*Conclusion:* The results of single case trials must admittedly be interpreted with caution. However this case suggests rapid and dramatic improvement in an mTB patient as determined by computer graded testing and blinded third party assessment following the introduction of the PoNS unit and rehabilitation protocols. This documented improvement occurred in spite of inadequate response obtained by the patient following months of aggressive traditional neurological rehab through a neurological specialty center. Given the growing problem of mTBI and persistent post-concussional symptoms and the limited therapeutic options for treatment, the PoNS unit and CN-NINM warrants study in controlled trials of mTBI treatment.

#### **Minimally invasive treatment of chronic subdural haematomas with Subdural Evacuating Port System (SEPS)**

Norbert Lekka<sup>1</sup>, István Farkas<sup>2</sup>, Sándor Zsolczai<sup>1</sup>, Tibor Mózer<sup>1</sup>, György Szeifert<sup>1</sup>

<sup>1</sup>Péterfy Trauma Center, Budapest

<sup>2</sup>St. John's Hospital, Budapest